

**I.V. Kovach**<sup>1</sup>,  
**O.V. Korchak**<sup>4</sup>,  
**E.N. Dychko**<sup>3</sup>,  
**Kh.A. Buniatian**<sup>1</sup>,  
**Yu.V. Khotimska**<sup>1</sup>,  
**V.V. Gargin**<sup>2</sup>,  
**Y.V. Lavreniuk**<sup>1</sup>

## USE OF ODONTOTROPIC MATERIAL IN TREATMENT OF TRAUMATIC PULPITIS IN EXPERIMENT

Dnipro State Medical University<sup>1</sup>

V. Vernadsky str., 9, Dnipro, 49044, Ukraine

e-mail: kristinabunyatyanyan@gmail.com

Kharkiv National Medical University<sup>2</sup>

Nauka av., 4, Kharkiv, 61000, Ukraine

Dnipro Medical Institute of Traditional and Non-Traditional Medicine<sup>3</sup>

Sevastopolska, 2, Dnipro, 49000, Ukraine

Kyiv Medical University<sup>4</sup>

Boryspilska str., 2, Kyiv, 02099, Ukraine

e-mail: terdent@kmu.edu.ua

Дніпровський державний медичний університет<sup>1</sup>

вул. В. Вернадського, 9, Дніпро, 49044, Україна

Харківський національний медичний університет<sup>2</sup>

пр. Науки, 4, Харків, 61000, Україна

Дніпровський медичний інститут традиційної та нетрадиційної медицини<sup>3</sup>

вул. Севастопольська, 17, Дніпро, 49000, Україна

ПВНЗ «Київський медичний університет»<sup>4</sup>

вул. Бориспільська, 2, Київ, 02099, Україна

**Цитування:** Медичні перспективи. 2021. Т. 26, № 4. С. 144-152

**Cited:** Medicni perspektivi. 2021;26(4):144-152

**Key words:** experimental pulpitis, biological method of treatment, paste with tricalcium silicate

**Ключові слова:** експериментальний пульпіт, біологічний спосіб лікування, паста з трикальційсилікатом

**Ключевые слова:** экспериментальный пульпит, биологический способ лечения, паста с трикальцийсилікатом

**Abstract.** Use of odontotropic material in treatment of traumatic pulpitis in experiment. Kovach I.V., Korchak O.V., Dychko E.N., Buniatian Kh.A., Khotimska Yu.V., Gargin V.V., Lavreniuk Y.V. The problem of diagnosis and effective treatment of one of the most common complications of dental caries, such as pulpitis, including pediatric patients, is still quite relevant at the present time. Considering anatomy-physiological and age-related features of temporary and permanent teeth in children, the rapid and aggressive course of the carious process in poorly mineralized hard tissues due to the untimely and incomplete "maturation" of them, it is beyond any doubts that scientists and practitioners involved in pediatric dentistry deal with such complications in the clinic much more often than when dealing with adults. A particularly risky group are those who develop decompensated caries, according to classification by T.F. Vinogradova. Therefore, the search for more advanced methods of diagnosis and treatment of both acute and chronic inflammation of pulp, especially with the preservation of its viability, is logical and relevant in modern dentistry. Existing methods for the biological treatment of pulpitis have their positive aspects, but possible complications up to necrosis or pulp gangrene in remote terms indicate the need for improvement both the choice of a more effective method with clear indications for its use, and the technology and material of odontotropic direction. The aim of the work was to study the results of treatment of pulpitis in experimental animals by using tricalcium silicate cement for its further application in the clinic. An experimental study was conducted on 18 animals (9-month-old male rabbits, Dutch breed) in vivarium setting to obtain information on the morphogenetic mechanisms of regeneration of living tissues and cells of dental pulp in which traumatic pulpitis was induced artificially. By the nature of odontotropic material, four groups of experimental animals were divided into: group I (control) – traumatic pulpitis was treated without special odontotropic paste, group II - treatment of pulpitis with material based on calcium hydroxide, group III - material with trioxide aggregate, group IV - material with tricalcium silicate. Every two, four, and six weeks from the moment the animals were introduced into the experiment, the damaged teeth were removed and treated in a certain way and, after special treatment, were amenable to histological examination. In the pulp tissue, the state of its main components was studied: stroma, cellular elements and blood vessels of the microvasculature. After excretion of

animals from the experiment on the 2nd and 6th weeks tissues of tooth were fixed in 10% formalin. Fixed in formalin tissue has been routine proceeding after decalcification in acetic acid with making histological slides which were stained with hematoxylin and eosin (H&E), according to van Gieson, Mallory, PAS-reaction was performed. The slides were studied with the microscope "Olympus BX-41" and followed interpretation by "Olympus DP-soft version 3.2", which was used for morphometric study. Statistical comparison was performed using Mann-Whitney test for statistical analysis. The accepted level of significance was  $p < 0.05$ . Studying the state of the pulp in the phase of acute traumatic pulpitis in dynamic observation for a month and half period, at the end of the second, fourth and sixth week the possibility of a stable restoration of the viability of the pulp as well as all its components was clearly proven. If at the beginning of a morphological study, pulp injury was accompanied by clear signs of aseptic inflammation, both cellular, vascular and stromal formations, then after a month and a half there were signs of a clear restoration of pulp viability in the biological treatment of artificial pulpitis of the second, third and fourth study groups. The most significant dynamic signs of microscopic formations of the pulp were noted in animals of the fourth study group treated with odontotropic paste with tricalcium silicate. The ability of this paste to complete tissue restoration in a short time period was proven. Therefore, it should be noted that artificially induced pulpitis in experimental animals is accompanied by significant breakages in the viability of the main components of pulp tissue, such as stromal fibers, microvasculature vessels and cellular elements. Filling and odontotropic materials in pastes for capping of the damaged pulp, such as calcium hydroxide, trioxide aggregate and tricalcium silicate, have full potential for restoring the viability of injured pulp, but with varying degree of effectiveness. According to histological research, biological material with tricalcium silicate is the most effective one for restoration of the pulp in a short time period.

**Реферат. Застосування одонтоотропного матеріалу при лікуванні травматичного пульпіту в експерименті. Ковач І.В., Копчак О.В., Дичко Є.Н., Бунятян Х.А., Хотимська Ю.В., Гаргін В.В., Лавренук Я.В.** Проблема діагностики та ефективного лікування одного з найбільш поширених ускладнень карієсу зубів, яким є пульпіт, у тому числі в дитячому віці, є і в теперішній час достатньо актуальною. Особливості анатомії та фізіології тимчасових та постійних зубів у дітей, швидкий і навіть агресивний перебіг каріозного процесу в слабо мінералізованих твердих тканинах у зв'язку з недосконалим та незавершеним етапом їх «дозрівання», поза сумнівом, призводять до того, що в клініці подібні ускладнення виникають значно частіше, ніж у дорослих. Особливо ризиковану групу складають особи з декомпенсованим карієсом за класифікацією Т.Ф. Виноградової. Тому пошук більш досконалих способів діагностики та лікування як гострого, так і хронічного запалення пульпи, особливо зі збереженням її життєздатності, є логічним та актуальним у сучасній стоматології. Існуючі способи біологічного лікування пульпіту мають свої позитивні сторони, але можливі ускладнення аж до некрозу та гангрені пульпи у віддалені терміни свідчать про необхідність удосконалення як вибору ефективного способу за чіткими показаннями, так і технології та матеріалу одонтоотропного спрямування. Метою дослідження стало вивчення результату лікування пульпіту в експериментальних тварин шляхом застосування трикальційсилікатного цементу для подальшого використання в клініці. Матеріали й методи: вивчення ефективності лікування штучного травматичного пульпіту біологічним способом з використанням одонтоотропної пасти різного складу на чотирьох групах тварин (кролі-самці голландської породи у віці 9 міс.). За характером одонтоотропного матеріалу чотири групи експериментальних тварин розподілені на I групу (контрольну) – де лікування пульпіту було без використання спеціальної одонтоотропної пасти, II групу – лікування з матеріалом на основі гідрооксиду кальцію, III групу – матеріал з тріоксидаагрегатом, IV групу – матеріал з трикальційсилікатом. Кожені два, чотири та шість тижнів з моменту введення тварин в експеримент видалені пошкоджені та вилікувані зуби після спеціальної обробки піддавались гістологічному дослідженню. У тканині пульпи вивчали стан основних її компонентів: стромі, клітинних елементів та судин мікроциркулярного русла. Вивчення стану пульпи у фазі гострого травматичного пульпіту в динамічному спостереженні протягом 1,5 місяця в кінці другого, четвертого та шостого тижня чітко довело можливість стійкого відновлення життєздатності пульпи і всіх її компонентів. Якщо на початку морфологічного дослідження травма пульпи супроводжувалась явними ознаками асептичного запалення як клітинних, судинних утворень, так і стромі, то через 1,5 міс. було досить відчутне відновлення життєздатності пульпи при біологічному лікуванні штучного пульпіту другої, третьої та четвертої групи тварин. Найбільш значущі динамічні ознаки мікроскопічних утворень пульпи відбулись у тварин четвертої дослідної групи, де лікування пульпіту проводили з використанням одонтоотропної пасти з трикальційсилікатом. Доведена спроможність цієї пасти до повного відновлення життєздатності пульпи в короткий термін. Слід зазначити, що штучно викликаний травматичний пульпіт в експериментальних тварин супроводжується суттєвими пошкодженнями життєздатності основних компонентів тканин пульпи, якими є волокна стромі, судини мікроциркуляторного русла та клітин пульпи, він має класичні ознаки запального процесу. Застосовані матеріали одонтоотропних паст для покриття пошкодженої пульпи, такі як гідрооксид кальцію, тріоксид агрегату, трикальційсилікат, володіють повноцінними можливостями для відновлення життєздатності травмованої пульпи, хоча і з різним ступенем ефекту. Найбільш ефективним для відновлення пульпи за короткий термін, за даними гістологічного дослідження, виявився біологічний матеріал з трикальційсилікатом.

The problem of diagnosis and effective treatment of one of the most common complications of dental caries, which is pulpitis, including pediatric patients is still quite relevant [4, 6, 8, 10]. Considering anatomy-physiological and age-related features of temporary and permanent teeth in children, the rapid and aggressive course of the carious process in poorly mineralized hard tissues due to the untimely and incomplete “maturation” of them, it is beyond any doubts that scientists and practitioners involved in pediatric dentistry deal with such complications in the clinic much more often than when dealing with adults, especially in the dispensary group of decompensated caries by T.F. Vinogradova. Therefore, it becomes quite logical to search for more advanced modern methods of diagnosis and treatment of inflammation of pulp tissues of different genesis, including cariogenic. Clear and objective diagnosis of the nature and localization of the inflammatory process provides an opportunity to clarify the indications for the choice of pulpitis treatment and in the clinic biological one is preferable. It is necessary to recognize the imperfection of clinical and instrumental methods of diagnosis of pulpitis of both acute and chronic forms, which significantly reduces the effectiveness of treatment and even causes a progressive course and the occurrence of further complication - periodontitis. Therefore, according to

the research of specialists, the most informative one should recognize the morpho-histological way of studying the state of inflammation of the tissues of the pulp, which in clinical conditions is almost impossible. But to study more effective ways of biological treatment of inflammation of the pulp is always an urgent problem and this opportunity provides experimental study in animals [2, 3, 5, 7, 9].

Therefore, the aim of the work was to study the result of treatment of pulpitis in experimental animals by the use of tricalcium silicate cement for its later use in the clinic.

**MATERIALS AND METHODS OF RESEARCH**

An experimental study was conducted on 18 animals (9-month-old male rabbits, Dutch breed) in vivarium setting to obtain information on the morphogenetic mechanisms of regeneration of living tissues and cells of dental pulp in which traumatic pulpitis was induced artificially. Subsequently, the inflammation of the pulp was treated by the method of applying odontotropic biological material directly to the tissue of the pulp. Animals were divided into four observation groups (Table 1) by the nature of the odontotropic material, 18 teeth in each group. Statistical comparison was performed using Mann-Whitney test for statistical analysis. The accepted level of significance was  $p < 0.05$ .

Table 1

**Distribution of experimental animals by odontotropic material in the treatment of traumatic pulpitis (n=number of study subjects)**

Groups of animals	Material used
I n=6	Control, without paste treatment
II n=4	Material based on calcium hydroxide
III, n=4	Material with mineral trioxide aggregate
IV n=4	Material with tricalcium silicate

Teeth of animals were damaged in the conventional way, under 5% ketamine, of 0.4 ml per 1 kg of body weight, intramuscularly anesthesia The animals were sacrificed at the end of the 2nd, 4th and 6th week, the removed teeth were fixed in 10% formalin solution. After routine procedures, the slices were made, stained with hematoxylin and eosin according to van Gieson modified reaction by Mallory, PAS-reaction was performed [1]. The stained slides were examined under microscope

“Olympus BX-41” and further processed by “Olympus DP – soft version 32” software.

The procedure was strictly in accordance with the Declaration of Helsinki, European Convention for the Protection of Vertebrate Animals (18.03.1986), Directive of the Council of the European Economic Society for the Protection of Vertebrate Animals (24.11.1986). Dnipropetrovsk Medical Academy (01.04.2016).



## RESULTS AND DISCUSSION

Acute damage to the dental pulp in the animals of the comparison group was accompanied by overt signs of traumatic pulpitis. In this case, there were inflammatory changes in the entire mass of the pulp-stroma, cellular elements of blood vessels, nerve formations, etc. Thus, the cellular composition of the pulp, represented by specialized cells of peripheral odontoblasts, subodontoblasts, fibroblasts and sedentary macrophages in the more central areas of the

pulp has a tendency to deform. A large group of cells is represented by fibroblasts with many sprouts with characteristic syncytial associations. Their cytoplasm is orthochromatic and PAS-negative. Marked changes were also observed in sedentary macrophages - changes in their shape up until significant deformation, with cytoplasm having a weak PAS-positive reaction. Morphometric data are presented in table 2 for that and other groups.

Table 2

Morphometric data of pulp for investigated groups ( $M \pm m$ ,  $\times 10^2$  per  $1 \text{ mm}^2$ )

Investigated parameter	Intact group	Group of calcium hydroxide			Group of MTA			Group of tricalcium silicate		
		2 weeks	4 weeks	6 weeks	2 weeks	4 weeks	6 weeks	2 weeks	4 weeks	6 weeks
Odontoblasts, $\times 10^3$ per $1 \text{ mm}^2$	8.3 $\pm$ 1.02	2.41 $\pm$ 0.44*	3.01 $\pm$ 0.82	3.05 $\pm$ 0.92*#	2.58 $\pm$ 1.11*	4.01 $\pm$ 1.62	5.95 $\pm$ 1.53#	3.92 $\pm$ 1.03*	5.22 $\pm$ 1.62	7.98 $\pm$ 1.51#
Fibroblasts, $\times 10^2$ per $1 \text{ mm}^2$	17.92 $\pm$ 4.42	5.31 $\pm$ 2.18*	8.43 $\pm$ 1.76	11.47 $\pm$ 2.16#	5.78 $\pm$ 1.62	11.42 $\pm$ 2.64	16.04 $\pm$ 2.20	10.71 $\pm$ 2.36	14.23 $\pm$ 2.18	16.63 $\pm$ 3.11

Notes: \* –  $p < 0.05$  compared to the intact animals; # –  $p < 0.05$  compared to 2 weeks group.

There is a significant accumulation of neutrophils. In the cytoplasm of odontoblasts, the

presence of granular or fine-grained PAS-positive material around the nucleus is noted (Fig. 1, 2).

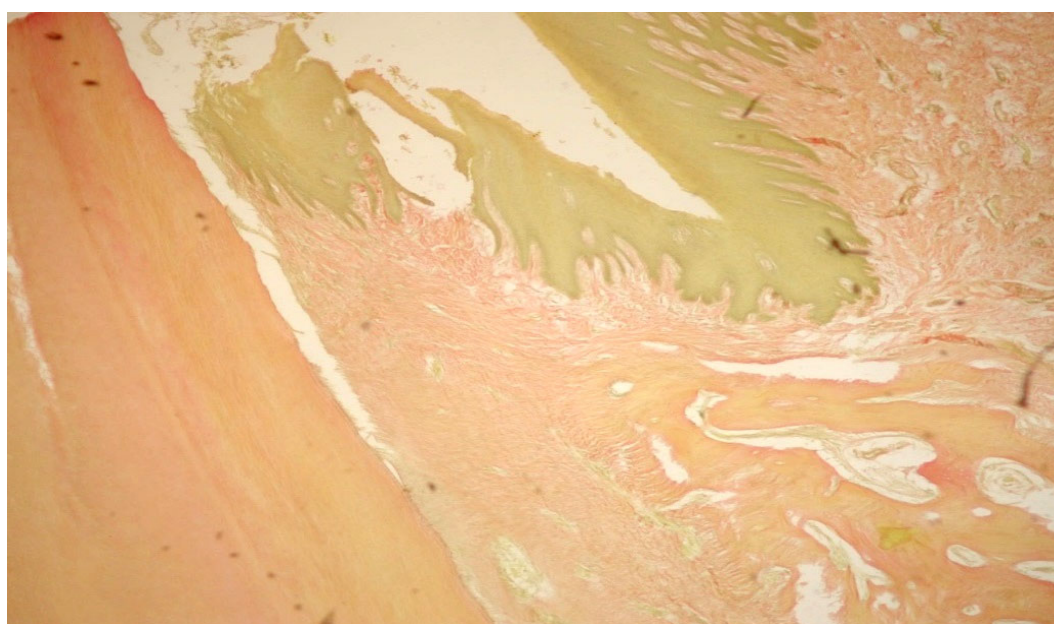
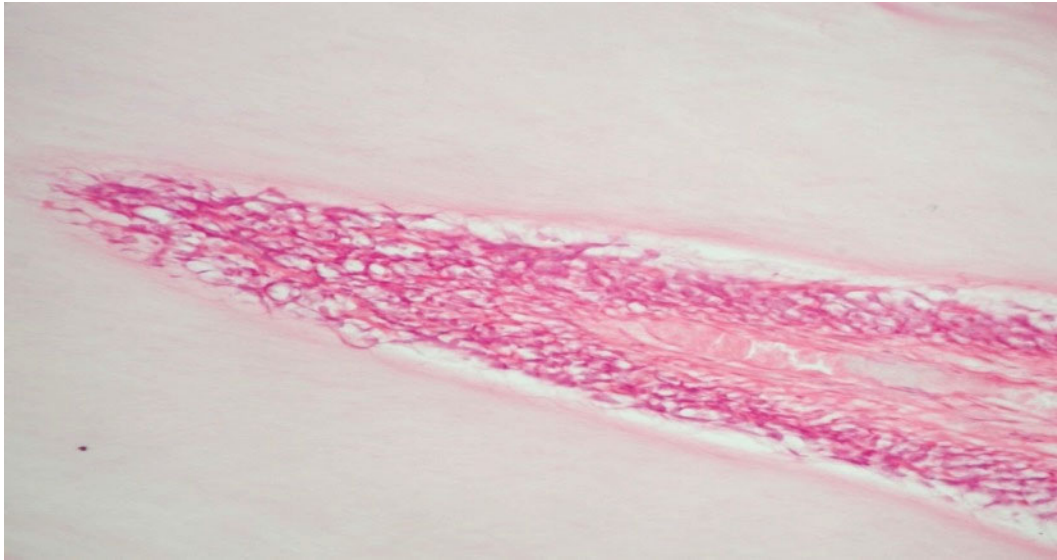


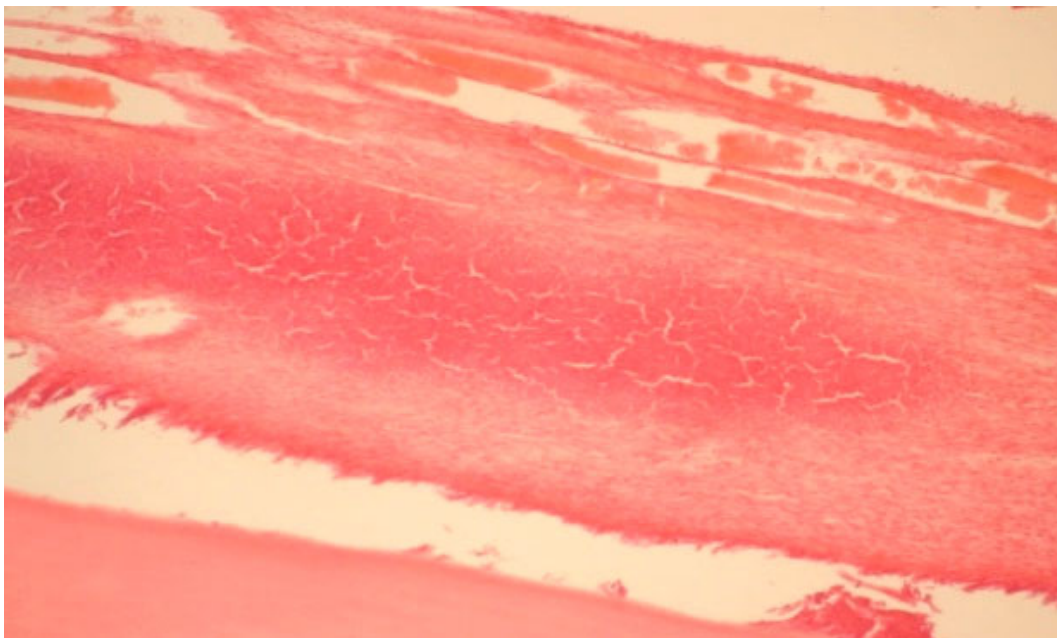
Fig. 1. Fuchsinophilia of collagen fibers. Staining by van Gieson  $\times 200$



**Fig. 2. The association of odontoblasts with dentin and pulp fibroblasts. A large number of vessels of the microvasculature. Staining with hematoxylin and eosin  $\times 200$**

Significant changes of inflammatory character took place in the vessels of the damaged pulp. Due to the presence of tissue swelling, hyperemia, hemorrhages and signs of necrobiotic phenomena,

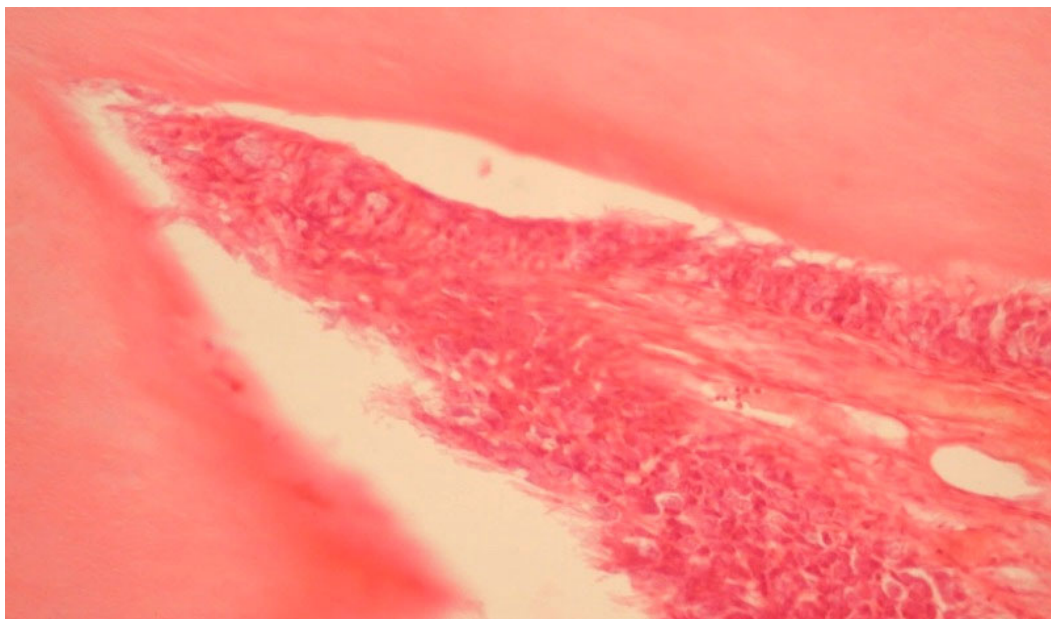
tinctorial properties of separate components of the tissue with disintegration of reticulin fibers, homogenization of the basic substance and accumulation of PAS-positive substance occur (Fig. 3).



**Fig. 3. Perivascular hemorrhages. Staining with hematoxylin and eosin  $\times 100$**

In addition, traumatic pulpitis is accompanied by damage in the form of accumulation of inflammatory cells, such as neutrophils and macrophages. In the fibroblasts expressed dystrophic phenomena with anemic nuclei develop. Substantial changes in


the form of cytoplasmic vacuoles occur in odontoblasts. Such cellular changes are aggravated with the progression of the inflammatory process in the pulp up to the necrosis of separate sections of the pulp tissue (Fig. 4).



**Fig. 4. Vascularization of odontoblasts. Staining with hematoxylin and eosin ×100**

However, the pulp has its reserve to the pathway of its restoration with the decrease in inflammatory phenomena – a small infiltration of fibroblasts,

proliferative activity of vascular endothelium and the appearance of macrophages with vacuolated cytoplasm (Fig. 5).



**Fig. 5. Initial connecting reaction around the microabscess. Staining by van Gieson ×100**

Traumatic inflammation of the pulp is also accompanied by significant changes in the elements of

the stroma. So, in the collagen fibers there is an accumulation of PAS – positive substances and this

phenomenon does not abate due to incubation with amylase. Only after acetylation the reaction disappeared completely. Occasionally, there are signs of osteodentin apposition. Trauma of the pulp tissue is accompanied by the appearance of hemorrhagic infiltrates and hematoma more in the coronal than in the root area. That pulp is prone to restoration in the form of deposits of replacing dentin.

Numerous cases of damage to the hard dental tissues of experimental animals were noted in the form of the appearance of significant dentin defects with penetration into the pulp. A number of cases was accompanied by the formation of abscesses with the accumulation of fibrous tissue, which can be regarded as a productive process. Dentification of false parietal denticles without dentinal tubules as a product of odontoblasts function is observed everywhere.

In some cases cicatrization in the pulp tissue both in the matrix and blood vessels occurs, red cell adherence syndrome, plasmorrhagia and parietal blood clots develop.

These pathohistological characteristics reproduce the state of the anatomic-histological elements of the pulp damaged due to mechanical trauma.

The study of systematic groups of animals according to biological paste, with which a direct capping of the injured pulp was performed, revealed the characteristic morphological changes throughout the observation period. Two weeks after entering the experiment, the basic pulp tissue formations in all three groups of experimental animals treated from traumatic pulpitis by applying calcium hydroxide paste (II group), mineral trioxide aggregate (III group) and paste with tricalcium silicate (IV group) were investigated.

So in animals of the second group where calcium hydroxide paste was used, layer of odontoblasts in the area of pulp trauma was absent, the latter was present only in the area of the root of the tooth. Subodontoblastic and central pulp layer is saturated with inflammatory cellular elements, sites of necrosis, significant accumulation with neutrophils and macrophages were identified.

Allongside with that, capillary vessels are plethoric with signs of hemorrhage. In the walls of the capillaries, an increase in the PAS-reaction of the membranes is noted, and in the area of pulp damage – deposition of vacuolated PAS-positive substance. In these areas, an excessive number of neurophiles, macrophages, eosinophils, plasmocytes takes place. The cytoplasm of the odontoblasts is vacuolated and the fibroblasts have signs of inflammatory infiltration.

In the group of animals with damaged pulp treated with mineral trioxide aggregate (MTA), a positive change was observed already after two

weeks. Thus, on the border of the crown and root pulp, the tissue structure was completely restored and corresponded to the central layer of healthy pulp. But in the area of the pulp damage proper, signs of trauma and islands of necrosis persisted. The vessels were plethoric with edema, with neutrophils and macrophages accumulated around them. In the cells of odontoblasts near the zone of inflammation dystrophic changes were noted. In the prevascular space, small foci with accumulation of lymph- and plasmocytes were present. However, the signs of sclerosis in the nature of elastic and collagen fibers were noted. Reticular fibers are thickened, compacted and partially homogenized. There is a partial hyalinization of collagen fibers, PAS – reaction in these areas is weakly positive. In places around the plethoric blood vessels of the microcirculation there are signs of hemorrhage. In the area of the damaged pulp, a large number of neutrophils, macrophages, eosinophils and plasmocytes is still stored. Decay of reticular fibers is observed. The cytoplasm of the odontoblasts is vacuolated. But there are also signs of high proliferative activity and an increase in the density of the vessels of the microcirculation, the capillary network is more dense due to the appearance of young capillaries.

In the fourth group of experimental animals with damaged pulp treated with tricalcium silicate paste (TCS), already after two weeks of microscopic examination, markedly positive changes were observed, indicating a significant and appreciable therapeutic effect of this agent. It was characteristic that at least three histological layers were clearly observed in the area of traumatic pulp defect: the layer of colliquative necrosis, the layer of aseptic inflammation and the zone of unchanged structure of the pulp of all its components.

However, the layer of odontoblasts is slightly thinner than the control one, there is edema in the stroma, small foci of lymphocytes and plasmocytes accumulation, increased number of fibroblasts, single leukocytes occur, reticular fibers are coiled, thickened, in places – foci with partial homogenization. PAS – reaction of stroma fibers is slightly positive. Capillary vessels are enlarged, plethoric, their walls with enhanced PAS – reaction of membranes. There are signs of proliferative activity. The capillary network is more dense at the expense of young vessels.

All these histological signs testify to the significant potential of the damaged pulp to restore its viability under the influence of the chosen therapeutic agent, which is a paste with TCS.

Dynamic observation of the morphological pattern of the pulp tissues in experimental pulpitis in

animals 4 and 6 weeks after the beginning of the experiment showed that the biological method with odontotropic TCS paste is the most expressive and more accelerated one used for complete revitalization of almost all components of the pulp.

So the pulp in the area adjacent to the defect has signs of homogenization and mosaicism of interglobular dentin. The peritubular dentin is dense enough, margins of the tubules are clear, well expressed. On the border with the pulp, there is a clearly defined line of predentin, close to the layer of odontoblasts. There are no signs of abnormal changes in the parapulpal dentin. There is an increased vascularization of the microcirculatory vessels, especially in the area of a direct contact of the paste with TCS and pulp tissues. The appearance of young connective fibers is noted. That is, in the second month of the experiment, the full restoration of all pulpar elements – stroma fibers, cellular composition, vessels of the microvasculature under the influence of odontotropic paste TCS occurred clearly and fairly quickly.

It has been established that pulp tissue possesses high reactive capabilities [7, 9], while direct coating of the pulp promotes active regeneration processes with active formation of capillary net and new connective tissue elements [5]. Two weeks after injury, manifestations of protective adaptive mechanisms in the form of an inflammatory process with its resolution were found in it, encapsulation of dentinal fragments and foci of necrosis with their delimitation from viable pulp tissue with back-

ground of intensive angiogenesis [8]. The histological examination of pulp tissue at different times with using odontotropic paste of the second (paste with CH) and the third (paste with MTA) group of observations in artificial traumatic pulpitis showed a significant delay in terms of normalization of the damaged components – cellular, vascular and fibrous especially in animals of the second group. As a result, it should be agreed that the biological method of treating traumatic experimental pulpitis with using tricalcium silicate material has proven to be the most effective from the point of view of revitalization and short term of this recovery.

### CONCLUSIONS

1. Artificially induced traumatic pulpitis in experimental animals is followed by a significant damage to the viability of the main components of the tissue, which are stroma fibers, vessels of the microvasculature and pulp cells, being accompanied by the classic characteristics of the inflammatory process.

2. The materials used in odontotropic pastes – calcium hydroxide, mineral trioxide aggregate and tricalcium silicate for damaged pulp capping, have good qualities for restoring the viability of the injured pulp, although with varying degree of effect.

3. Biological material with tricalcium silicate proved to be the most effective one used for the recovery of pulp and with a short period of complete treatment according to histological examination.

Conflict of interests. The authors declare no conflict of interest.

### REFERENCES

1. Sarkisov D, Perov Y. [Microscopic Technique. A Guide for Physicians and Laboratory Assistants]. Moskva: Meditsina; 1996. Russian.
2. Tomás-Catalá CJ, Collado-González M, García-Bernal D, Oñate-Sánchez RE, et al. Biocompatibility of New Pulp-capping Materials NeoMTA Plus, MTA Repair HP, and Biodentine on Human Dental Pulp Stem Cells. *J Endod.* 2018;44(1):126-32. doi: <https://doi.org/10.1016/j.joen.2017.07.017>
3. Pinheiro LS, Iglesias JE, Boijink D, Mestieri LB, et al. Cell Viability and Tissue Reaction of NeoMTA Plus: An In Vitro and In Vivo Study. *Grecca FS4. J Endod.* 2018 Jun 1;pii S0099-2399:30169-9. doi: <https://doi.org/10.1016/j.joen.2018.03.007>
4. Mehrvarzfar P, Abbott P, Mashhadiabbas F, Vatanpour M, Tour Savadkouhi S. Clinical and histological responses of human dental pulp to MTA and combined MTA/treated dentin matrix in partial pulpotomy. *Australian Endodontic Journal.* 2018;44(1):46-53. doi: <https://doi.org/10.1111/aej.12217>
5. Khotimska Y, Kovach I, Buniatian K, Kravchenko L, Varzhapetian S. Comparaiv analesis of the effect of tricalcium silicat cement and mineral trioxide aggregate on the pulp after the vital amputation in experimental animals. *Medicni perspektivi.* 2019;24(4):145-53. doi: <https://doi.org/10.26641/2307-0404.2019.4.189606>
6. Kovach I, Buniatian K, Makarevych A, Verbytska A, Gargin V. Influence of Tricalcium silicate on course of traumatic pulpitis. *Georgian medical news.* 2018;276(3):130-5. Available from: <http://repo.dma.dp.ua/id/eprint/3099>
7. Michael PA, Abbott P, Jacqueline CS. Hydroxyl lon diffusion through radicular dentine when calcium hydroxide is used under different conditions. *Materials.* 2018;11(1):152-60. doi: <https://doi.org/10.3390/ma11010152>



8. Tanomaru-Filho M, Torres FE, Chávez-Andrade GM, de Almeida M, et al. Physicochemical Properties and Volumetric Change of Silicone Bioactive Glass and Calcium Silicate-based Endodontic Sealers. *J Endod.* 2017;43(12):2097-101.  
doi: <https://doi.org/10.1016/j.joen.2017.07.005>

9. Poimenova A, Kitraki E, Kakaboura A, Rahiotis C. Early responses of human pulp to direct capping

with resin adhesive systems and calcium hydroxide. *Dent Mater.* 2018;34(4):e73-e82.

doi: <https://doi.org/10.1016/j.dental.2018.01.018>

10. Ji E, Song J, Kim S, Jeon M, Choi B, Lee J. Viability of pulp stromal cells in cryopreserved deciduous teeth. *Cell And Tissue Banking.* 2013;15(1):67-74.

doi: <https://doi.org/10.1007/s10561-013-9375-z>

## СПИСОК ЛІТЕРАТУРИ

1. Саркисов Д. С., Перов Ю. Л. Микроскопическая техника: руководство для врачей и лаборантов. Москва: Медицина, 1996. 544 с.

2. Biocompatibility of New Pulp-capping Materials NeoMTA Plus, MTA Repair HP, and Biodentine on Human Dental Pulp Stem Cells / C. J. Tomás-Catalá et al. *J. Endod.* 2018. Vol. 44, No. 1. P. 126-132.  
DOI: <https://doi.org/10.1016/j.joen.2017.07.017>

3. Cell Viability and Tissue Reaction of NeoMTA Plus: An In Vitro and In Vivo Study / L. S. Pinheiro et al. Grecca FS4. *J. Endod.* 2018. 1 Jun. (pii S0099-2399). P. 30169-9. DOI: <https://doi.org/10.1016/j.joen.2018.03.007>

4. Clinical and histological responses of human dental pulp to MTA and combined MTA/treated dentin matrix in partial pulpotomy / P. Mehrvarzfar et al. *Aust Endod J.* 2018. Vol. 44, No. 1. P. 46-53.  
DOI: <https://doi.org/10.1111/aej.12217>

5. Comparaiv analesis of the effect of tricalcium silicat cement and mineral trioxide aggregate on the pulp after the vital amputation in experimental animals / Y. Khotimska et al. *Медичні перспективи.* 2019. Т. 24, № 4. С. 145-153.  
DOI: <https://doi.org/10.26641/2307-0404.2019.4.189606>

6. Influence of Tricalcium silicate on course of traumatic pulpitis / I. Kovach, et al. *Georgian medical news.* 2018. Vol. 276, No. 3. P. 130-135.

URL: <http://repo.dma.dp.ua/id/eprint/3099>

7. Michael P. A., Abbott P., Jacqueline C. S. Hydroxyl ion diffusion through radicular dentine when calcium hydroxide is used under different conditions. *Materials.* 2018. Vol. 11, No. 1. P. 152-160.

DOI: <https://doi.org/10.3390/ma11010152>

8. Physicochemical Properties and Volumetric Change of Silicone Bioactive Glass and Calcium Silicate-based Endodontic Sealers / M. Tanomaru-Filho et al. *J. Endod.* 2017. Vol. 43, No. 12. P. 2097-2101.

DOI: <https://doi.org/10.1016/j.joen.2017.07.005>

9. Poimenova A., Kitraki E., Kakaboura A., Rahiotis C. Early responses of human pulp to direct capping with resin adhesive systems and calcium hydroxide. *Dent Mater.* 2018. Vol. 34, No. 4. P. e73-e82.

DOI: <https://doi.org/10.1016/j.dental.2018.01.018>

10. Viability of pulp stromal cells in cryopreserved deciduous teeth / E. Ji et al. *Cell and tissue banking.* 2013. Vol. 15, No. 1. P. 67-74.

DOI: <https://doi.org/10.1007/s10561-013-9375-z>

Стаття надійшла до редакції  
10.12.2020

