

9. Nazeer N, Ivaturi PB. Proptosis in Otorhinolaryngology: An Overview. *Int Arch Otorhinolaryngol.* 2021 Apr;25(2):e267-72. Epub 2020 Jun 30. PMID: 33968231; PMCID: PMC8096516. doi: <https://doi.org/10.1055/s-0040-1709986>

10. Sebaa B, Benkeroum D, Hadjadj C, Sahbatou R. Thrombophlébite du sinus caverneux d'origine infectieuse chez l'enfant: Revue de la littérature et de scription d'un cas. *Revue Médicale de l'HMRUO.* 2015;1(2):55-58.

Стаття надійшла до редакції
17.05.2021



UDC 616.136-005.6-06:616.988:578.834]-036.1-089

<https://doi.org/10.26641/2307-0404.2022.1.254332>

A.R. Stasyshyn *,
I.S. Stadnyk,
A.I. Doroshak,
I.M. Polianytsia,
R.L. Bokhonko,
T.M. Demianovych,
O.B. Matviychuk

MESENTERIC THROMBOSIS IN PATIENTS WITH CORONAVIRUS DISEASE: COMPREHENSIVE ASSESSMENT AND TREATMENT

*Danylo Halytskyi Lviv national medical university
Pecharska str., 69, Lviv, 79010, Ukraine*

*Львівський національний медичний університет ім. Данила Галицького
вул. Пекарська, 69, Львів, 79010, Україна*

**e-mail: astasyshyn@i.ua*

Цитування: *Медичні перспективи.* 2022. Т. 27, № 1. С. 86-91

Cited: *Medicni perspektivi.* 2022;27(1):86-91

Key words: *mesenteric thrombosis, coronavirus, assessment and treatment*

Ключові слова: *порушення мезентеріального кровообігу, коронавірусна інфекція, комплексна оцінка та лікування*

Ключевые слова: *нарушение мезентериального кровообращения, коронавирусная инфекция, комплексная оценка и лечение*

Abstract. Mesenteric thrombosis in patients with coronavirus disease: comprehensive assessment and treatment.

Stasyshyn A.R., Stadnyk I.S., Doroshak A.I., Polianytsia I.M., Bokhonko R.L., Demianovych T.M., Matviychuk O.B.

Acute mesenteric circulatory disorder belongs to the most serious diseases of the abdominal cavity. Being an emergency condition, it is associated with high mortality. Coronavirus infection is an anthroponotic disease in the group of acute respiratory infections, is characterized by damage to the upper respiratory tract, severe intoxication, coagulopathy and in severe cases - multiple organ failure. The aim of the work was to analyze the results of the surgical treatment of mesenteric vascular thrombosis in patients with COVID-19. We have studied the results of diagnostics and treatment of 13 patients (9 males and 4 females) with acute mesenteric thrombosis and COVID-19. We have analyzed patients' complaints and the clinical picture of the disease, as well as performed general medical examination (routine blood and urine tests, biochemical parameters, coagulogram), X-ray examination of abdominal and thoracic cavities, computed tomography / angiography of abdominal organs, diagnostic laparoscopy, diagnostic mini-laparotomy and laparotomy. The symptoms of the disease include nausea, vomiting, abdominal pain, diarrhea, fever, cough, shortness of breath and belching. The disease was diagnosed by contrast computed tomography. Four patients developed simultaneous thrombosis – stroke, thrombosis of the portal and mesenteric veins, splenic and renal infarction, thrombosis of the superior mesenteric and portal veins. Six patients have been suffering from underlying health

conditions, 7 patients – had none. Ten patients underwent surgery (laparotomy with resection of the nonviable intestine), 3 – received conservative treatment (heparin therapy). Six patients died (4 out of 10 – during surgery and 2 out of 3 – during conservative treatment). Postoperative mortality was 40%.

Реферат. Тромбоз мезентеріальних судин у хворих на COVID-19: комплексна оцінка та лікування. Стасишин А.Р., Стадник І.С., Дорошак А.І., Полянниця І.М., Бохонко Р.Л., Дем'янович Т.М., Матвійчук О.Б. Гостре порушення мезентеріального кровообігу належить до категорії найтяжчих захворювань органів черевної порожнини, є невідкладною ситуацією і пов'язане з високим рівнем смертності. Коронавірусна інфекція – антропонозне захворювання з групи гострих респіраторних інфекцій, яке характеризується ураженням верхніх відділів респіраторного тракту, вираженою інтоксикацією, розвитком коагулопатії, при тяжкому перебігу – поліорганною недостатністю. Мета дослідження – проаналізувати результати хірургічного лікування тромбозу мезентеріальних судин у хворих з COVID-19. Проаналізовано результати діагностики та лікування 13 хворих (9 чоловіків, 4 жінки) з гострим тромбозом брижових судин у поєднанні з COVID-19. Проведено аналіз скарг пацієнтів та клінічної картини захворювання, загальноклінічні лабораторні обстеження (загальний аналіз крові, сечі, біохімічні показники, коагулограма), оглядова Rtg органів черевної та грудної порожнини, комп'ютерна томографія /ангіографія органів черевної порожнини, діагностичні лапароскопія, мінілапаротомія та лапаротомія. Симптоматикою захворювання були: нудота, блювання, біль у животі, діарея, лихоманка, кашель, задишка, відрижка. Діагноз встановлено за допомогою комп'ютерної томографії з контрастом. У 4 пацієнтів відзначено одночасний тромбоз в інших місцях – гостре порушення мозкового кровообігу, тромбоз ворітної та брижової вен, інфаркти селезінки та нирок, тромбоз верхньої брижі та ворітної вени. У 6 пацієнтів були супутні захворювання, у 7 пацієнтів – жодного. Десять пацієнтів оперовані (лапаротомія з резекцією нежиттєздатної кишки), а 3 – отримали консервативне лікування (гепаринотерапія). Шість пацієнтів померли (4 з 10-х при операційному лікуванні і 2 з 3-х – при консервативному). Післяопераційна летальність – 40%.

Acute mesenteric thrombosis belongs to the most severe disorders of the abdominal cavity. Its mortality reaches 95-97% [9]. According to the European Society for Vascular Surgery (ESVS), in 2017 100% of non-operated patients and 80-90% of operated patients died. The reasons for such high mortality are the rapid irreversible changes in the intestinal wall, unclear clinical symptoms of the disease, resulting in late diagnosis and surgery, most often being palliative [5, 11]. Mesenteric circulatory disorders can be both acute and chronic. While the acute course is accompanied by intestinal infarction with necrosis, chronic one causes functional disorders without necrotic changes in the intestinal wall. According to ESVS, 2017, the occurrence of acute mesenteric circulatory disorders ranges from 0.2 to 0.3 per 10,000 population per year and more often (almost twice) such disorders occur in women over 60. The sources of embolism of mesenteric vessels are intracardiac thrombi or thrombotic vegetations on the heart valves (in heart failures, cardioclerosis, endocarditis, myocardial infarction, aortic aneurysm and aortic thrombosis) [4]. When it comes to the factors that contribute to intravascular thrombosis, many of them, both endogenous and exogenous are usually seen, COVID-19 including. Among the causes of thrombosis, the American Board of Surgeons identifies:

1. Changes in the vessel wall related to endothelial damage, narrowing of the lumen of blood vessels as a result of its spasm, external compression, inflammation, changes in the permeability of its wall.

2. Slowing of blood flow, which includes all the changes in cardiac activity that cause vascular congestion, resulting in the development of thrombosis.

3. Changes in physical and clinical properties of blood.

Acute mesenteric thrombosis has 3 stages [1] which develop sequentially. Stage I (ischemia) is when the arterial blood flow is completely or partially stopped. The metabolic products start accumulating immediately; they are not initially absorbed due to circulatory disorders and therefore the intoxication is insignificant. Stage II is characterized by infarction and progressive necrosis of the intestinal wall. At this stage, blood flow is relatively restored, since the concomitant angiospasm disappears and the dilation of collaterals occurs. At the same time, plasma and formed elements of blood enter the intestinal lumen and abdominal cavity. Stage III (peritonitis) is not always manifested, mainly because patients die before its development from severe intoxication, deponing of blood, severe hypovolemia and concomitant metabolic disorders.

Coronavirus infection (COVID-19) is an anthropotic disease in the group of acute respiratory infections (ARI), which occurs in all seasons of the year and is characterized by damage to the upper respiratory tract and mild intoxication with a positive prognosis, except for some special variants – severe acute respiratory syndrome (SARS), Middle East respiratory syndrome coronavirus (MERS-CoV) and coronavirus disease 2019. In the whole world, almost 79.1 million people have fallen ill since the beginning of the pandemic (+663 thousand in these days), more than 1,7 million died (+13 429) and above 55.6 million recovered (+515 thousand) based on WHO statistics [7].

The pathogenesis of COVID-19-activated coagulopathy has several mechanisms: DIC syndrome with multiorgan failure, which occurs more often in absence of anticoagulant prophylaxis, and may happen due to septic complications [6, 10]. Pulmonary intravascular coagulopathy (MicroLOTS) is thrombosis of the microcirculatory tract, a condition accompanied by local and systemic thrombocytopenic coagulopathy. Recent pathomorphological studies have revealed thrombosis of the branches of the pulmonary artery of small and medium caliber, as well as microthrombi in the alveolar capillaries in most of lethal cases. Thrombi in the large branches of the pulmonary artery were observed in 9-33% of cases. In contrast to the Acute Respiratory Distress Syndrome associated with influenza, microcirculatory disorders in a new coronavirus infection are characterized by endothelial damage with the destruction of the cell membrane. The main difference between SARS and COVID-19 is the presence of extrapulmonary microvascular thrombi found in the capillaries of the kidneys, intestines, and skin. It is well known that SARS-CoV-2 enters the cells by endocytosis after binding to the protein of the transmembrane angiotensin-converting enzyme – 2 (ACE-2), which is expressed in cells of the lungs, heart, blood vessels, kidneys and gastrointestinal tract. Section of studies has identified viral RNA and pathogen particles in the intestine, brain, and subcutaneous vein cells [8, 11]. Elevated levels of Wilbrand factor in patients with severe infection can cause thrombotic microangiopathy, specifically in the intestinal vessels. The thromboinflammatory response may be mediated by endothelial damage or active macrophages, leading to a cytokine storm [4].

The aim of the work – to analyze the results of the treatment of mesenteric vascular thrombosis in patients with COVID-19.

MATERIALS AND METHODS OF RESEARCH

We have studied the results of diagnostics and treatment of 13 patients (9 males and 4 females) with acute mesenteric thrombosis and COVID-19, who underwent treatment in the Surgical clinic of Faculty of postgraduate education of Danylo Halytskyi Lviv national medical university and Lviv clinical municipal emergency hospital. The average age of the patients was 56. The average duration of the disease from the first clinical signs to hospitalization was 48 hours.

The research was conducted in accordance with the principles of bioethics set out in the WMA Declaration of Helsinki – “Ethical principles for medical research involving human subjects” and “Universal Declaration on Bioethics and Human Rights” (UNESCO).

We have analyzed patients’ complaints and the clinical picture of the disease, as well as performed a general medical examination (routine blood and

urine tests, biochemical parameters, coagulogram), X-ray examination of abdominal and thoracic cavities, computed tomography (CT) / angiography of abdominal organs, diagnostic laparoscopy, minilaparotomy and laparotomy. The diagnosis of COVID-19 in all patients was confirmed by polymerase chain reaction (PCR) and computed tomography of the chest. Diagnosis and treatment were carried out in accordance with the Order of the Ministry of Health of Ukraine dated 31.12.2020 No. 3094 "On amendments to the protocol «Provision of medical care for the treatment of coronavirus disease (COVID-19)».

Statistica 10.0 (StatSoft) was used to perform statistical data analysis. Data analysis was based on three types of research: 1) descriptive statistics, 2) testing for normality of distribution, 3) statistical significance testing of differences. The level of significance for statistical tests was chosen to be 5%, so the null hypothesis was rejected at $p < 0.05$ [2].

RESULTS AND DISCUSSION

Acute mesenteric ischaemia is an emergency condition, associated with high mortality. Surgical diagnosis requires a high index of suspicion and early contrast CT. The diagnosis was based on contrast-enhanced CT. Since the pathological mechanism leading to thrombosis of mesenteric vessels in COVID-19 is not well-defined today, there is a chance of direct viral invasion into the intestinal tissue, with the expression of ACE-2 on enterocytes, target receptors for SARS-Cov-2 or viral infection of endothelial cells, leading to diffuse endothelial inflammation or enhancement of procoagulation factors such as von Willebrand factor, fibrinogen induced by a cytokine storm, causing coagulation and fibrinolysis. An additional explanation for hypercoagulation may be a large number of prothrombotic circulating microvesicles – cytoplasmic microparticles formed from platelets or monocytes and neutrophil extracellular traps released from activated neutrophils, a mixture of nucleic DNA, histones, and nucleosomes. Symptoms of the disease include nausea, vomiting, abdominal pain, diarrhea, fever, cough, shortness of breath and belching. The disease was diagnosed by contrast CT. Four patients have experienced a simultaneous thrombosis in other places – stroke, thrombosis of the portal and mesenteric veins, splenic and renal infarction, thrombosis of the superior mesenteric and portal veins. Six patients have been suffering from underlying health conditions but 7 patients from none. Ten patients underwent surgery (laparotomy with resection of the nonviable intestine), and 3 patients underwent conservative treatment (heparin therapy). Six patients died (4 out of 10 – during the surgery and 2 out of 3 – during conservative treatment). Postoperative mortality is 40%.

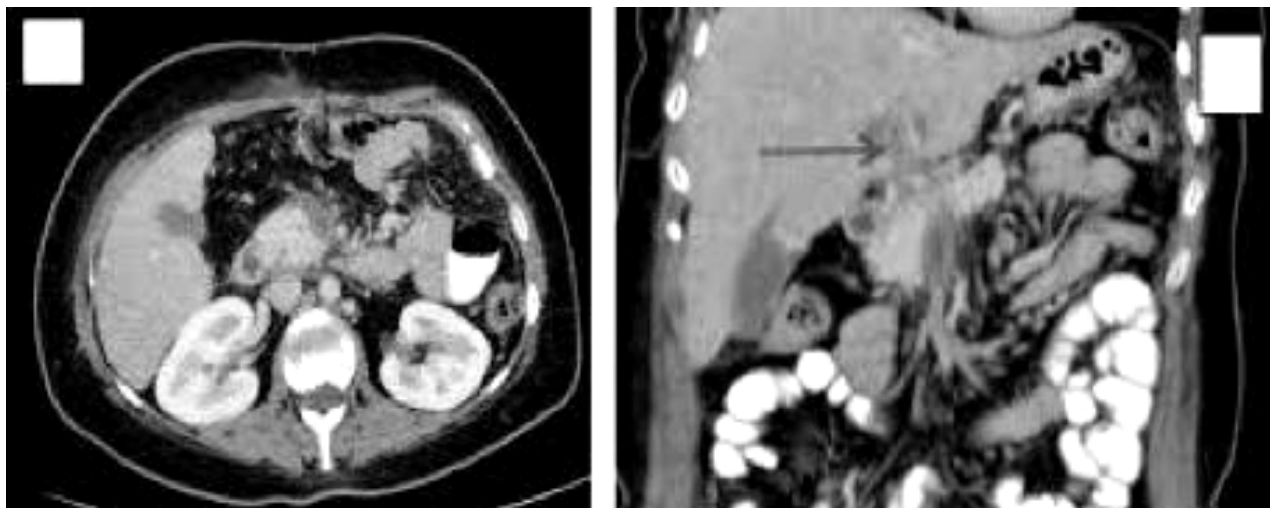


Fig. 1. CT-angiography of mesenteric thrombosis in patient K., 58 y.o.

At the pre-hospital stage the following intravenous injections should be administered:

1. 150 ml of normal saline / 30,000 IU heparin and 40,000 IU of Fibrinolysin + 1 ml of 2% Omnopon or 1-3 ml of Droperidol + 1 ml of 0.1% Atropine solution + 120 ml of Neohaemodes + 200 ml of 5% Na₂CO₃ solution 250 ml of Rheopolyglucin + 125 ml of Hydrocortisone + 5 ml of 5% vitamin C, 1 ml of 6% vitamin B₂, 1 ml of 5% vitamin B₆ solution.

2. In suppressed cardiovascular activity and hypotension: Mezatone 1 ml of 1%, Norepinephrine 1.0, Cordiamine 2 ml.

3. In circulatory disorders: Strophanthin: 0.5 ml of 0.05% solution, 0.5 ml of 0.06% Corglycon solution with 20% glucose solution.

Anticoagulant therapy for the treatment of hospitalized patients who were in the surgical departments – enoxaparin (average – 1 mg/kg, every 12 hours once a day) 4000 anti-Xa MO (40 mg; 0.4 ml) twice a day provided creatinine clearance >30 ml/min. For patients in the intensive care unit, enoxaparin 8000 anti-Xa MO (80 mg; 0.8 ml) twice daily for patients with creatinine clearance >30 ml/min. In case of severe renal dysfunction – enoxaparin 4000 anti-Xa MO (40 mg; 0.4 ml) twice a day.

Surgical treatment according to the European Society for Vascular Surgery is as follows [9]:

1. In case of no surgery on the vessels of the peritoneum indicated, the resection of the intestine is performed within the vascular occlusion.

2. In large vascular occlusions – resection of a gut is not performed.

3. With limited damage – resection 20-25 cm from the affected area.

4. If the peritoneal blood flow can be restored during surgery, then only the obvious areas of intestinal gangrene need to be removed and the borders of the resection are closer to the necrotic tissues.

5. Surgery: thrombus-/embolectomy should be performed not later than 5-6 hours after total occlusion of the vessel.

Conservative therapy (systemic heparin therapy, thrombolysis, endovascular interventions) for mesenteric thrombosis is effective in some cases, though it can be dangerous because of the inability to assess the viability of the intestine. A good alternative is to combine conservative therapy with the laparoscopic intestine assessment. However, considering the lung damage in patients with COVID-19, pneumoperitoneum may worsen the respiratory failure. Most likely, the optimal choice can be laparotomy with intestinal revascularization and resection of non-viable segments. Early detection of mesenteric thrombosis is extremely important in this situation. The key aspect in the treatment of this complication is the vigilance of clinicians, early CT angiography, and surgical treatment. However, there is currently insufficient evidence to say for sure what treatment tactic is the most appropriate. There is a need for qualitative clinical trials in the future to optimize the treatment and diagnostic process and as much as possible minimize mortality in patients with COVID-19 complicated by mesenteric vascular thrombosis.

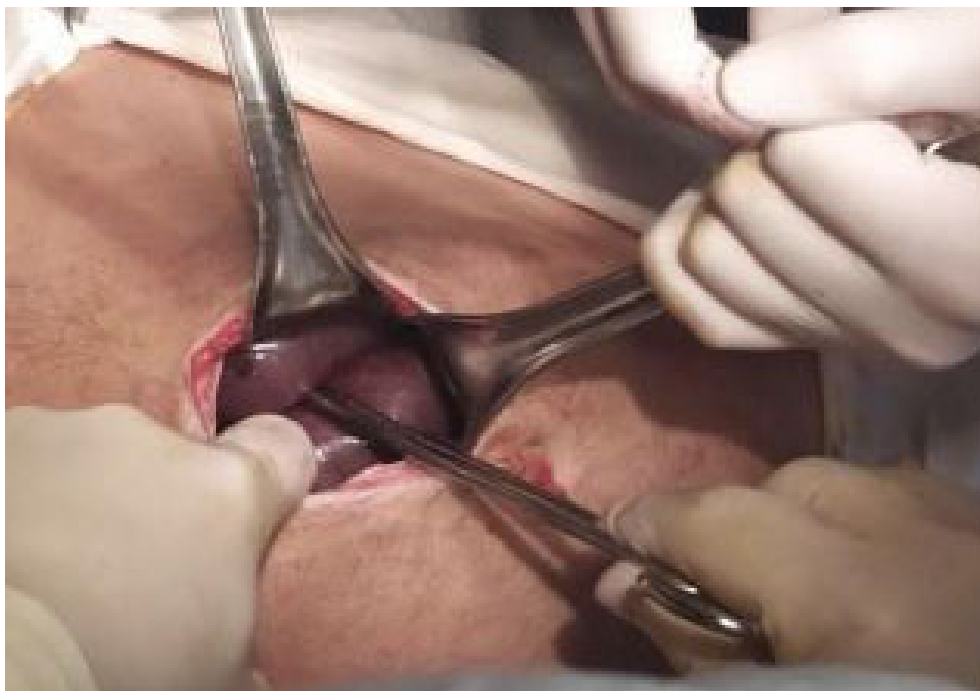

Fig. 2. Diagnostic mini-laparotomy in mesenteric thrombosis of the first segment of the superior mesenteric artery in patient M., 53 y.o. with COVID-19

At the stage of intestinal ischemia, vascular surgeries have been performed. At the infarction stage – vascular surgery in combination with intestinal resection or intestinal resection only.

The final decision on the non-viability of the remaining intestinal loops was made only after the

vascular surgery. An important role is played by early relaparotomy in patients who underwent interventions for acute mesenteric thrombosis, with increasing necrotic changes in the intestinal wall. Relaparotomy should be performed not earlier than 8-10 hours after the initial surgery.

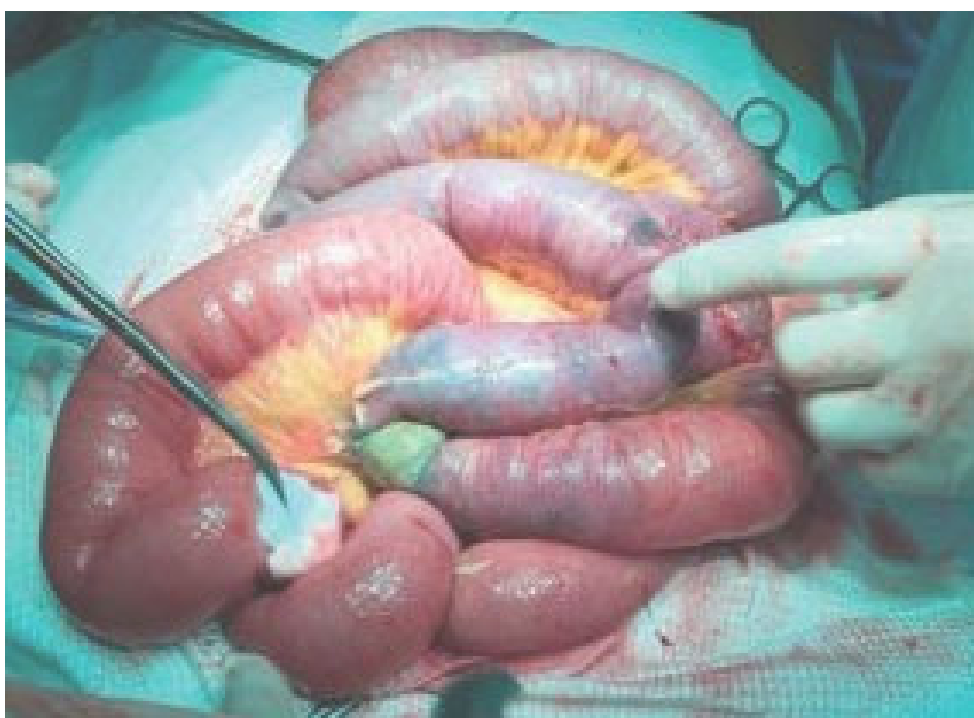

Fig. 3. Diagnostic laparotomy, patient M., 69 y.o.

The key purpose of the postoperative intensive care was:

1. Correction of hemodynamic disorders, maintenance of circulating blood volume, improvement of microcirculation, circulation in the tissues.

2. Normalization of gas exchange up to the use of artificial lung ventilation.

3. Satisfying metabolic and organic needs of the body with the use of drugs of parenteral food, not less than 4000 calories. Administration of anabolic hormones is suggested.

4. Preventive and therapeutic measures for preventing renal and hepatic failure. Using inhibitors of proteolytic enzymes, vitamins, cocarboxylase in combination with osmодиuretics.

5. Measures for normalizing intestinal motility.

6. Rational antibiotic therapy for prevention of wound infection and purulent complications.

CONCLUSIONS

1. Considering the COVID-19 pandemic and the growing number of patients with mesenteric thrombosis, we can find out the cause-effect relationship between these two diseases, in particular, coagulopathic complications in patients with COVID-19 in the form of mesenteric thrombosis.

2. Acute mesenteric ischemia is a serious complication of COVID-19, which has high mortality rate and can occur as a late complication (in average, 7 days).

3. The “gold” standard for diagnosing mesenteric thrombosis is intravenous contrast computed tomography.

4. Treatment should include a set of conservative and surgical procedures: embolectomy and vascular stenting. In case of non-viable intestine, resection should be done. In total mesenteric thrombosis, surgery is palliative.

Contributors:

Stasyshyn A.R. – conceptualization, project administration, supervision;

Stadnyk I.S. – investigation, formal analysis;

Doroshak A.I. – writing – review & editing;

Polianytsia I.M. – writing – original draft;

Bokhonko R.L. – methodology, validation;

Demianovych T.M. – visualization;

Matviychuk O.B. – software, data curation.

Funding. This research received no external funding.

Conflict of interests. The authors declare no conflict of interest.

REFERENCES

- Farina D, Rondi P, Botturi E, Renzulli M, Borghezi A, Guelfi D, et al. Gastrointestinal: Bowel ischemia in a suspected coronavirus disease (COVID-19) patient. *Journal of Gastroenterology and Hepatology*. 2020;36(1):41-41. doi: <https://doi.org/10.1111/jgh.15094>
- Glantz S. [Biomedical statistics]. Moscow: Practice; 1998. p. 459. Russian.
- Kaur P, Qaqa F, Ramahi A, Shamoony Y, Singhal M, Shamoony F. Acute upper limb ischemia in a patient with COVID-19. *Hematology/Oncology and Stem Cell Therapy*; 2020. doi: <https://doi.org/10.1016/j.hemonc.2020.05.001>
- Kaur S, Bansal R, Kollimuttathuillam S, Gowda AM, et al. The looming storm: Blood and cytokines in COVID-19. *Blood Reviews*; 2020 Mar.;46:100743. doi: <https://doi.org/10.1016/j.blre.2020.100743>
- Khesrani LS, Chana K, Sadar FZ, Dahdouh A, Ladjadj Y, Bouguermouh D. Intestinal ischemia secondary to Covid-19. *J Pediatr Surg Case Rep*. 2020 Oct.;61:101604. doi: <https://doi.org/10.1016/j.epsc.2020.101604>
- Levolger S, Bokkers RPH, Wille J, Kropman RHJ, de Vries JPM. Arterial thrombotic complications in COVID-19 patients. *J Vasc Surg Cases Innov Tech*. 2020;6(3):454-9. doi: <https://doi.org/10.1016/j.jvscit.2020.06.012>
- Mitchell JM, Rakheja D, Gopal P. SARS-CoV-2-related Hypercoagulable State Leading to Ischemic Enteritis Secondary to Superior Mesenteric Artery Thrombosis. *Clin Gastroenterol Hepatol*. 2020 Jun 17:S1542-3565(20)30835-1. doi: <https://doi.org/10.1016/j.cgh.2020.06.024>
- Pacioni C, Ponton S, Francavilla S, Cuzzoli A. Arterial Mesenteric Thrombosis as a Complication of SARS-CoV-2 Infection. *Eur J Case Rep Intern Med*. 2020;7(5). doi: https://doi.org/10.12890/2020_001690
- Parry AH, Wani AH, Yaseen M. Acute Mesenteric Ischemia in Severe Coronavirus-19 (COVID-19): Possible Mechanisms and Diagnostic Pathway. *Acad Radiol*. 2020;27(8):1190. doi: <https://doi.org/10.1016/j.acra.2020.05.016>
- Singh B, Kaur P, Ajdir N, Gupta S, Maroules M. Covid-19 Presenting as Acute Limb Ischemia. *Cureus*. 2020;12(7):e9344. doi: <https://doi.org/10.7759/cureus.9344>
- Vulliamy P, Jacob S, Davenport RA. Acute aortoiliac and mesenteric arterial thromboses as presenting features of COVID-19. *Br J Haematol*. 2020;189(6):1053-4. doi: <https://doi.org/10.1111/bjh.16760>
- Yang S, Monnier-Cholley L, Arrivé L. Systemic arterial thrombosis and acute mesenteric ischemia in a patient with COVID-19. *Intensive Care Med*. 2020;46(7):1464-5. doi: <https://doi.org/10.1007/s00134-020-06079-2>

Стаття надійшла до редакції
06.01.2021